



TREATMENT OF ADOLESCENT IDIOPATHIC SCOLIOSIS WITH GLOBAL (ROD) DEROTATION MANEUVER USING PEDICLE SCREWS

Ozcan Kaya¹,
Turgut Akgul²,
Okan Ozkunt³,
Fatih Dikici⁴,
Onder Yazicioglu²,
Unsal Domanic²

¹Istinye University Bahcesehir Liv Hospital, Department of Orthopaedics and Traumatology, İstanbul, Turkey.

²Istanbul University, Medical Faculty of Istanbul, Department of Orthopaedics and Traumatology, İstanbul, Turkey.

³Medipol University Sefakoy Hospital, Department of Orthopaedics and Traumatology, İstanbul, Turkey.

⁴Acibadem University Atakent Hospital, Department of Orthopaedics and Traumatology, İstanbul, Turkey.

Address: Ozcan Kaya, Assistant Professor, Istinye University Bahcesehir Liv Hospital, Department of Orthopedics and Traumatology, Aşik Veysel Mah. Süleyman Demirel Cad. No:1, 34510, Esenyurt, İstanbul, Turkey.
Phone: +90 507 306 70 07
E-mail: ozcankaya.md@gmail.com
Received: 03rd September 2017
Accepted: 22th November, 2017.

ABSTRACT

Introduction: Adolescent idiopathic scoliosis is a three dimensional deformity. For the treatment of deformity, nature of deformity should be well understood and treatment strategy has to be directed to the coronal, sagittal and axial components of deformity. Global Derotation (GD) maneuver is based on simple rod derotation from concave side aiming to correct the deformity on coronal, sagittal and axial profile. In this report we reviewed AIS surgery results treated by global derotation maneuver with all pedicle screw instrumentation.

Material& Methods: Between 2003 and 2011, 253 patients had been operated using GD technique. 80 of 253 patients was included to our study. The patients routinely evaluated with preoperative-postoperative and last follow up standing ortho-x-rays. Coronal and sagittal profile parameters measured on x-rays with digital software using Cobb method. Rotational component of the deformity was measured according to Nash-Moe method at the apical vertebra.

Results: 80 patients (71 female ; 9 male) had been followed up average 19,8 (7-37) months. Patients age average were 15,1(12-21) at operation date. Coronal Cobb angle measure in thoracic curves preoperative were 48,9° decreased to mean 3,2° postoperatively. The mean coronal thoracolumbar curve were 45,8° preoperatively and decreased to mean 2°. Apical vertebra rotation measure regressed to mean 0,68 (0-1). Thoracic kyphosis showed downward tendency from mean 37,8° to mean 27,8°.

Conclusion: Rod derotation technique enable to correct coronal and axial profile. Coronal Cobb angle improvement seen obviously with correction of axial profile rotation. Sagittal hypokyphotic effect of GD should be kept in mind.

Key words: adolescent idiopathic scoliosis, derotation, pedicle screw

Level of Evidence: Retrospective clinical study, Level III

INTRODUCTION

Adolescent idiopathic scoliosis (AIS) is a three-dimensional spinal deformity, composed of coronal, sagittal and axial plane abnormalities. Surgical treatment of AIS evolved historically from compression-distraction rod applications to posterior pedicle screw instrumentation. Evolution to more powerful instrumentation, lead to better correction results with different correction maneuvers.

Harrington instrumentation system utilized distraction and compression forces correcting coronal correction but it was insufficient to correct sagittal and axial deformity as coronal deformity⁽⁸⁾. Thereafter Cotrel–Dubousset (CD) instrumentation and pedicle screw

instrumentation was introduced which provided correction in all three-dimensions with concave simple rod derotation (SRD)⁽⁴⁾.

Lee et al. introduced concept of direct vertebral body derotation (DVBD)⁽¹²⁾ and suggested the idea of better axial correction with DVBD compared with SRD or global derotation. These powerful corrective techniques have helped further reduce asymmetric rib prominences and address scoliotic curves in all three dimensions and studies about correction maneuvers exploring correction ability of coronal, sagittal and axial plane deformity favored vertebral body derotation technique⁽¹⁶⁾.

Recently long term results of posterior instrumentation with pedicle screw

pointed hypokyphotic effect on sagittal profile. In fact, the sagittal plane alignment seems to be closely tied to overall health related quality of life in patients with scoliosis⁽¹⁰⁾. The relative hypokyphosis of the thoracic spine can be addressed during surgery, and surgeons often attempt to reproduce the natural thoracic kyphosis intraoperatively with anterior approaches.

The aim of our study is to report the correction of AIS with simple concave rod rotation, in patients treated by posterior fusion for thoracic AIS using pedicle screws in a single institution.

PATIENTS AND METHODS

A retrospective review, based on a database search, was performed to identify all AIS patients who had undergone posterior spinal fusion with pedicle screw-only instrumentation using rod derotation (RD) between January 2003 and June 2011 at the institution. The inclusion criteria were: (1) diagnosis of adolescent idiopathic scoliosis; (2) preoperative, early postoperative and last follow up standing long cassette x rays (3) posterior fusion using pedicle screw-only construct; (4) a minimum clinical and radiographic follow-up of 6 months.

Radiologic Evaluation

Radiographic evaluation included standing posterior-anterior and lateral films on long-cassettes (90x30 cm), before and after surgery and at the latest follow-up. The Lenke et al.⁽¹³⁾ surgical classification of AIS was used to describe curve patterns. Cobb measurements⁽³⁾ of the major curves were obtained, and the lateral films were evaluated for thoracic kyphosis (T2-T12), lumbar lordosis (superior endplate of L1 to inferior endplate of L5) in digital software (Surgimap software (New York, New York, USA)). The vertebral rotation was measured from the preoperative, early postop and last follow-up x-rays according to Nash-Moe method⁽¹⁷⁾.

Surgical Procedures

Surgeries was performed one senior surgeon. The patients was prepared and draped prone position on radiolucent operating table. Midline incision and thoracolumbar fascia exposure was performed over spinous procesusus (SP). Paraspinal muscles were detached from SP subperiosteally. Pedicle screw instrumentation were performed from distal levels to proximal levels of the spine. Distal and proximal instrumentation levels were determined according to preoperative bending x rays and traction x-rays. Pedicle screw placement were checked by fluoroscopy anteroposterior and pedicle direction oriented views.

A rod is prepared according to sagittal profile and placed to concave side pedicle screws parallel to ground. Pedicle tap screws closed but not tightened. Proximal and distal vertebral levels attached to rod derotator firmly and rod derotation is performed from convex to concave side between 90 to 180. After derotation maneuver apical vertebra tap screw is tightened. Convex side rod is applied and tap screws are tightened. Prevention of remaining deformity is checked with fluoroscopy and in situ benders are used for compression distraction maneuvers. Shoulder asymmetry and pelvic tilt are checked according to intraoperative images (Figure-1.a,b,c).

Neurophysiologic Evaluation

Intraoperative neurophysiologic evaluation was performed with Stagnara wake up test before 2007 June, later than neuromonitorization has been used in all spine surgery cases in the department.

Statistical analysis

Statistical analysis performed with SPSS software (version 16.0, SPSS Inc., Chicago, IL, USA). After calculating standard deviation, repeating measurements of subgroup analysis were performed with Friedman Test. Recovery rate differences between groups explored with Kruskal Wallis test. ManWhitney U test was used as posthoc test in comparison of statistically significant parameters. $p < 0,05$ accepted as statistically significant.

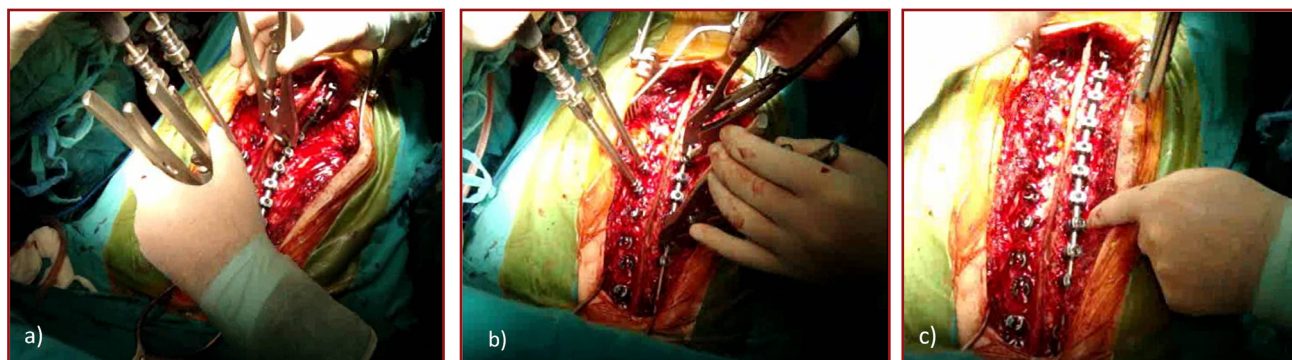


Figure-1. Intraoperative application of derotatuars and maneuver from convex side to concave side of the rod (global derotation) **a)** Proximal and distal attachment of derotatuars. **b)** Derotation maneuver from convex to concave side **c)** after the main maneuver remaining curve is corrected with distraction compression maneuvers.

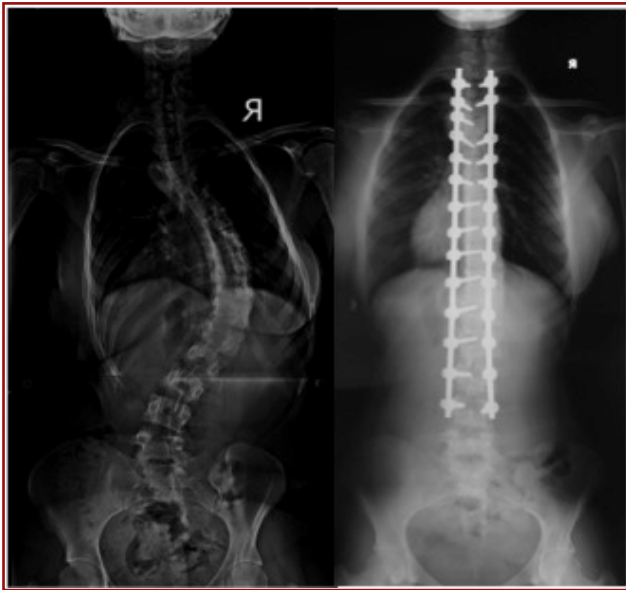


Figure-2. Preoperative and last follow up anteroposterior x-rays of 17 years old female patient with satisfying coronal curve correction

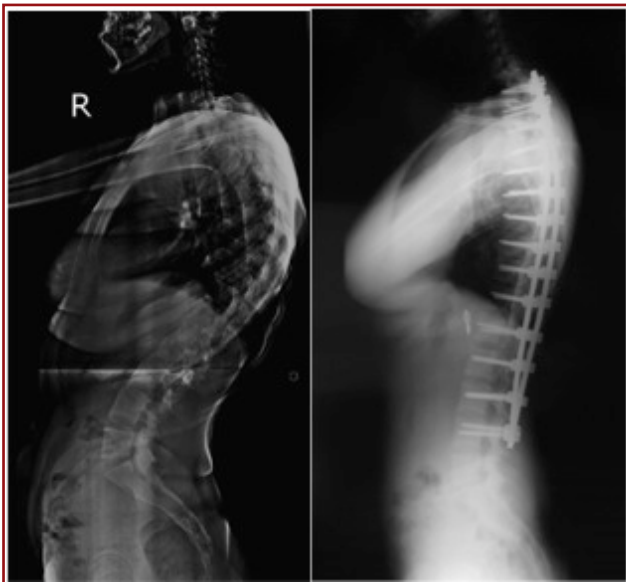


Figure-3. Preoperative and last follow up lateral x-rays showing sagittal plane changes.

RESULTS

Between 2003 and 2011, 253 patients had been operated using GD technique. 80 of 253 patients who met inclusion criteria's was included to our study. 71(89 %) female and 9 (11%) male patients enrolled to study. At the surgery time mean age was 15,1 (12 yo to 21 yo). Mean age was 14,7 yo (12 to 21yo) in females; 16,8 yo (13 yo -21 yo) in males. Mean follow up time was 19,8 months (7-37 months). Deformity classification was performed according to Lenke Classification. Subgroups were

as type 1 21 patients (%26,5);type 2 4 patients (%5);type 3 28 patients (%35) Lenke type 5 26 patients (%32,5) and 1 patient had type 6 curve pattern. Most upper instrumented vertebra was T2 and most lower instrumented vertebra was L5. The mean fused levels were 11,3 (7-13).The longest fusion site was between T2 and L4.

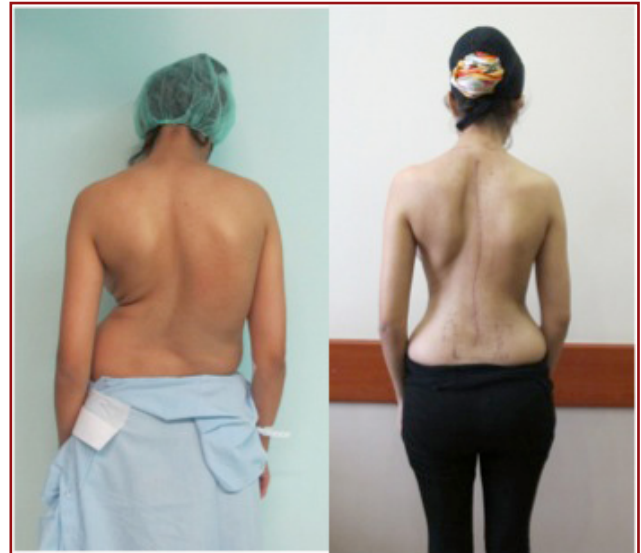


Figure-4. Preoperative and follow up clinical photographs with satisfying clinical appearance

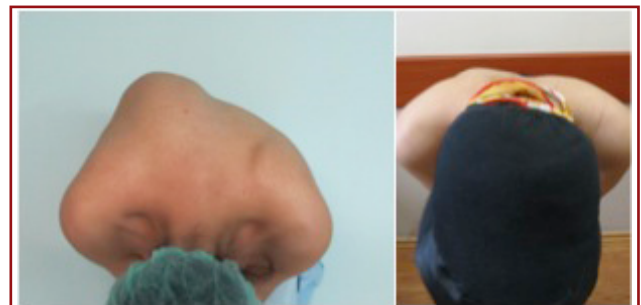


Figure-5. Rib Hump correction without thoracoplasty of same patient.

Coronal profile major curve cobb angles were mean 48,9° (between 42° and 61°) in main thoracic curves; mean 45,8° (between 41°and 69°) in thoracolumbar curves; mean 42,6° (between 36° and 54°) in lumbar curves preoperatively. At last follow up coronal cobb angle was mean 3,2° in main thoracic group; mean 2 in thoracolumbar group and mean 4,5° in major lumbar curve group. Statistically there were no difference between early postop curve magnitude and last follow up curve magnitude ($p>0,05$). Mann Whitney U test revealed that Lenke type 1 curves was most beneficial group from the surgery in terms of curve correction in coronal plane.

Sagittal plane analysis were performed with thoracic kyphosis and lumbar lordosis. Preoperative thoracic kyphosis was mean 37,1° (between 33° and 49°) and preoperative lumbar lordosis

was mean 52° (between 34° and 59°). Thoracic kyphosis (TK) was mean 27,8° and lumbar lordosis (LL) was 44,1° at last follow up. Early postoperative and follow up magnitude difference was not meaningful statistically. (p>0,05)

Apical vertebra rotation (AVR) was determined according to Nash-Moe method on preoperative postoperative and follow up x-rays. Preoperative mean AVR was 2,26 (between 2 and 3) and 0,68 at last follow up. Statistically AVR correction with surgery was found to be meaningful. (p<0,05) (Table-1).

Major complication (neurologic deficit, deep wound infection requiring implant removal, need of revision because of pseudoarthrosis or implant failure) and minor complications (superficial wound infection) was not recorded. One patient was diagnosed superior mesenteric artery syndrome after surgery. She underwent duodenojejunostomy procedure and recovered from the condition. She is doing well now.

DISCUSSION

Adolescent idiopathic scoliosis (AIS) is a three-dimensional spinal deformity, composed of coronal, sagittal and axial plane abnormalities. Surgical treatment of AIS evolved historically from compression distraction rod applications to posterior pedicle screw instrumentation. Evolution to more powerful instrumentation, lead to better correction results with different correction maneuvers.

Harrington introduced hook rod system in early 1960s in surgical treatment of scoliosis⁽⁸⁾. Concave side distraction convex side compression maneuvers resulted in some coronal plane correction but sagittal and axial profile could not be managed with use of Harrington instrumentation. Flat

back deformity, loss of correction, long fusion levels and pseudoarthrosis has been seen after use of Harrington rods⁽¹²⁾. At this point new instrumentation systems and corrective maneuvers has been developed to solve three plane deformity. Cotrel and Dubousset introduced the method of curve rotation technique with multi hook segmental instrumentation⁽⁴⁾. With the rod derotation maneuver toward concavity, It was named single concave rod rotation. Pedicle screw system development brought advantages of rigid fixation and easy manipulation of vertebral body through pedicles. The development of instrumentation over years has allowed increasing control of the coronal and sagittal plane deformities⁽²²⁾. Pedicle screw constructs have become commonplace in AIS surgery. Studies comparing hook and pedicle screw constructs reported more better correction in coronal plane deformity with use of pedicle screw systems, but in sagittal plane pedicle screw systems caused hypokyphosis^(14,22-23).

In the study of Fu et al.⁽⁶⁾ at 2 years follow up, thoracic kyphosis resulted less of the preoperative value (14,5° ± 6,5° vs. 15,8° ± 10,7°) in patients treated with screws, in contrast with increased kyphosis obtained at follow up with hook construct. Also increased implant density with pedicle screw constructs thought to be related thoracic hypokyphosis. Clements et al reported positive correlation between hypokyphosis and increasing implant density⁽²⁾.

Early papers which studied Cotrel-Dubousset single rod derotation maneuver reported that the derotation could induce a three dimensional correction. However recent reports criticized the rotational correction even though they generally find the corrections are satisfactory in both coronal and sagittal plane⁽¹²⁾.

Table-1. Patient demographics and measurement results.

	Preoperative	Follow Up
Sex		
Female	71(%89)	
Male	9 (%11)	
Mean age (yo)	15,1(12-21)	
Lenke Subtypes		
Type 1	21(%26,5)	
Type 2	4 (%5)	
Type 3	28(%35)	
Type 4	-	
Type 5	26(%32,5)	
Type 6	1 (%1)	
Coronal Cobb angle(°)		
-Thoracic	48,9° (42°-61°)	3,2°(0°-9°)
-Thoracolumbar	45,8°(41°-69°)	2° (0°-8°)
-Lumbar	42,6°(36°-54°)	4,5°(0°-11°)
Sagittal Cobb angle (°)		
T2-T12	37,1°(33°-49°)	27,8°(23°-41°)
Lumbar Lordosis (°)	52°(34°-59°)	44,1° (34°-47°)
Apical Vertebra Rotation	2,26 (2-3)	0,68(0-1)

Lee et al. introduced direct vertebral rotation (DVR) technique in 1999. DVR provided transverse plane vertebral rotation maneuver in addition to well-known single rod rotation posteromedialization effect. According to Lee, at first it was thought that DVR would only give better rotational correction than RD, however DVR provided better correction on coronal and sagittal planes⁽¹²⁾. Our present study showed satisfactory results in terms of coronal plane Cobb angles with rod derotation technique. In a prospective comparative cohort study of DVR versus RD, no significant difference was found between two groups in terms of coronal Cobb angle⁽²⁴⁾.

Pedicle screw use and derotation maneuvers may have a negative impact on the sagittal profile. Our results showed thoracic hypokyphosis with all pedicle screw construct and RD. Also thoracic pedicle screw instrumentation without a direct vertebral derotation, has been found to enhance a loss of sagittal profile in AIS investigating studies⁽¹⁶⁾. Studies confirmed the hypokyphotic effect of derotation maneuver with the exception of Lee et al that obtained a moderate increase of kyphosis with DVR, and Vallespir et al. that maintained the preoperative kyphosis^(12,25). The impression is that derotation with screw systems could increase lordosis trend on thoracic kyphosis in AIS patients. The derotation may have a lordogenic effect due to the translation of the overgrown vertebral body from the lateral to an anterior position. In the 3D simulation study of Watanabe, kyphosis was reduced after complete correction of the coronal and rotational deformity, but it was maintained after the coronal-only correction. These results proved the hypothesis that the vertebral derotation obtained by PS causes hypokyphosis of the thoracic spine⁽²⁶⁾.

In the present study axial correction of the apical vertebral bodies and rotational profiles simply measured from x rays as defined by Nash and Moe preoperatively and postoperatively⁽¹⁷⁾. Postoperative spinal instrumentation covered landmarks on standard x-rays. In the follow up x-rays we evaluated the pedicle screw direction and midline relation. CT has been largely accepted as the most accurate method to evaluate the vertebral rotation pre and postoperatively⁽¹⁾.

Axial vertebral rotation is thought to contribute to clinical rib hump. This rib hump is a major concern to patients and their families who consider it the second most important reason for surgery⁽¹⁹⁾. More recently attention has focused on strategies to improve correction of vertebral rotation with the key aim of further reducing rib hump. Surgeons have performed thoracoplasty to correct preoperative rib hump. Some authors stated long term negative effects of thoracoplasty especially on pulmonary function test, although some surgeons have found no long term deleterious effect of thoracoplasty in adolescents^(11,21). Pankowski et al⁽¹⁸⁾ reported the decrease in rib hump in both DVR and RD group, he found significantly better correction was achieved by DVR in contrast Tang et al reported almost the same rib hump correction with DVR and RD⁽²⁴⁾. Last studies explored relation between rotation techniques and health related quality of life (HRQOL) questionnaires⁽⁵⁾. DVR and RD groups showed similar results

of HRQOL questionnaires. In a prospective comparative cohort study there were not significant difference between DVR and RD in terms of rib hump correction and patient based HRQOL assessment⁽²⁴⁾.

Our study limitations were small number of patients which cannot reflect general population, our study designed as retrospective case control study without control group; only we could compare preoperative and postoperative results. Apical vertebra rotation measure technique is open to criticism because of inadequate evaluation from postoperatively instrumented x-rays.

In conclusion, there is little proof favoring new derotation techniques compared with RD technique. There is some weak evidence, with negative effect of radiation exposure to growing teenagers, which suggests improved vertebral derotation on CT with these new techniques. DVR or vertebral coplanar alignment technique appear to require thoracoplasty to correct significant rib hump at similar rates to traditional RD. DVR and RD seems to cause similar thoracic hypokyphosis on sagittal plane which could be caused all pedicle screw instrumentation actually.

REFERENCE

1. Aaro S, Dahlborn M, Svensson L. Estimation of vertebral rotation in structural scoliosis by computer tomography. *Acta Radiol Diagn (Stockh)* 1978; 19: 990-992.
2. Clement JL, Chau E, Kimpe C, Vallade MJ. Restoration of thoracic kyphosis by posterior instrumentation in adolescent idiopathic scoliosis: comparative radiographic analysis of two methods of reduction. *Spine* 2008; 33: 1579-1587.
3. Cobb JR. Outline for the study of scoliosis. *AAOS Instr Course Lect* 1948; 5: 261-275.
4. Cotrel Y, Dubousset J, Guillaumat M. New universal instrumentation in spinal surgery. *Clin Orthop Relat Res* 1988; 227: 10-23.
5. Di Silvestre M, Lolli F, Bakaloudis G, Lolli F, Bakaloudis G, Maredi E, Vommaro F, Pastorelli F. Apical vertebral derotation in the posterior treatment of adolescent idiopathic scoliosis: myth or reality? *Eur Spine J* 2013; 22:313-323.
6. Fu G, Kawakami N, Goto M, Tsuji T, Ohara T, Imagama S. Comparison of vertebral rotation corrected by different techniques and anchors in surgical treatment of adolescent thoracic idiopathic scoliosis. *J Spinal Disord Tech* 2009; 22: 182-189.
7. Gitelman Y, Lenke LG, Bridwell KH, Auerbach JD, Sides BA. Pulmonary function in adolescent idiopathic scoliosis relative to the surgical procedure: a 10-year follow-up analysis. *Spine* 2011; 36: 1665-1672.
8. Harrington PR. Treatment of scoliosis: correction and internal fixation by spine instrumentation. *J Bone Joint Surg* 1962; 44-A: 591-610.
9. Hwang SW, Samdani AF, Cahill PJ. The impact of segmental and en bloc derotation maneuvers on scoliosis correction and rib prominence in adolescent idiopathic scoliosis. *J Neurosurg Spine* 2012; 16: 345-350.
10. Hwang SW, Samdani AF, Gressot LV, Hubler K, Marks MC, Bastrom TP, Betz RR, Cahill PJ. Effect of direct vertebral body derotation on the sagittal profile in adolescent idiopathic scoliosis. *Eur Spine J* 2012; 21: 31-39.

11. Kim YJ, Lenke LG, Bridwell KH, Kim KL, Steger-May K. Pulmonary function in adolescent idiopathic scoliosis relative to the surgical procedure. *J Bone Joint Surg* 2005; 87-A: 1534–1541.
12. Lee SM, Suk S, Chung ER. Direct vertebral rotation: a new technique of three-dimensional deformity correction with segmental pedicle screw fixation in adolescent idiopathic scoliosis. *Spine* 2004; (29)3: 343–349.
13. Lenke L, Betz R, Harms J, Bridwell KH, Clements DH, Lowe TG, Blanke K. Adolescent idiopathic scoliosis: a new classification to determine extent of spinal arthrodesis. *J Bone Joint Surg* 2001; 83-A: 1169–1181.
14. Lowenstein JE, Matsumoto H, Vitale MG, Weidenbaum M, Gomez JA, Lee FY, Hyman JE, Roye DP. Coronal and sagittal plane correction in adolescent idiopathic scoliosis: a comparison between all pedicle screws versus hybrid thoracic hook lumbar screw constructs. *Spine* 2007; 32: 448–452.
15. Mattila M, Jalanko T, Helenius I. En bloc vertebral column derotation provides spinal derotation but no additional effect on thoracic rib hump correction as compared with no derotation in adolescents undergoing surgery for idiopathic scoliosis with total pedicle screw instrumentation. *Spine* 2013; 38: 1576–1583.
16. Mladenov KV, Vaeterlein C, Stuecker R. Selective posterior thoracic fusion by means of direct vertebral derotation in adolescent idiopathic scoliosis: effects on the sagittal alignment. *Eur Spine J* 2011; 20: 1114–1117.
17. Nash CL, Moe JH. A study of vertebral rotation. *J Bone Joint Surg* 1969; 51-A(2): 223–229.
18. Pankowski R, Roclawski M, Ceynowa M, Mikulicz M, Mazurek T, Kloc W. Direct vertebral rotation versus single concave rod rotation low-dose intraoperative computed tomography evaluation of spine derotation in adolescent idiopathic scoliosis surgery. *Spine* 2016; (41)10: 864–871.
19. Pratt RK, Burwell RG, Cole AA, Webb JK. Patient and parental perception of adolescent idiopathic scoliosis before and after surgery in comparison with surface and radiographic measurements. *Spine* 2002; 27: 1543–1550, Discussion: 1551–1552.
20. Rushton PRP, Grevit MP. Do vertebral derotation techniques offer better outcomes compared to traditional methods in the surgical treatment of adolescent idiopathic scoliosis? *Eur Spine J* DOI:10.1007/s00586-014-3242-x
21. Suk SI, Kim JH, Kim SS, Lee JJ, Han YT. Thoracoplasty in thoracic adolescent idiopathic scoliosis. *Spine* 2008; 33: 1061–1067.
22. Suk SI, Lee CK, Kim WJ, Chung YJ, Park YB. Segmental pedicle screw fixation in the treatment of thoracic idiopathic scoliosis. *Spine* 1995; 20: 1399–1405.
23. Suk SI, Lee CK, Min HJ, Cho KH, Oh JH. Comparison of Cotrel-Dubousset pedicle screws and hooks in the treatment of idiopathic scoliosis. *Int Orthop*. 1994; 18: 341–346.
24. Tang X, Zhao J, Zhang Y. Radiographic, clinical and patients' assessment of segmental direct vertebral body derotation versus simple rod derotation in main thoracic adolescent idiopathic scoliosis: a prospective, comparative cohort study. *Eur Spine J* 2015; 24: 298–305.
25. Vallespir GP, Flores JB, Trigueros IS, Sierra EH, Fernández PD, Olaverri JC, Alonso MG, Galea RR, Francisco AP, Rodríguez de Paz B, Carbonell PG, Thomas JV, López JL, Paulino JI, Pitarque CB, García OR. Vertebral coplanar alignment: a standardized technique for three-dimensional correction in scoliosis surgery: technical description and preliminary results in Lenke type 1 curves. *Spine* 2008; 33: 1588–1597.
26. Watanabe K, Nakamura T, Iwanami A, Hosogane N, Tsuji T, Ishii K, Nakamura M, Toyama Y, Chiba K, Matsumoto M. Vertebral derotation in adolescent idiopathic scoliosis causes hypokyphosis of the thoracic spine. *BMC Musculoskelet Disord* 2012; 13: 99.